

Multicenter Safety and Practice for Off-Label Diagnostic Use of Ferumoxytol in MRI

Kim-Lien Nguyen, MD • Takegawa Yoshida, MD • Nikhita Kathuria-Prakash, MD • Islam H. Zaki, MD • Csanad G. Varallyay, MD, PhD • Scott I. Semple, PhD • Rola Saouaf, MD • Cynthia K. Riggsby, MD • Sokratis Stoumpos, MD • Kevin K. Whitehead, MD, PhD • Lindsay M. Griffin, MD • David Saloner, PhD • Michael D. Hope, MD • Martin R. Prince, MD, PhD • Mark A. Fogel, MD • Mark L. Schiebler, MD • Giles H. Roditi, MD • Aleksandra Radjenovic, PhD • David E. Newby, MD, PhD • Edward A. Newwelt, MD • Mustafa R. Bashir, MD • Peng Hu, PhD • J. Paul Finn, MD

From the Diagnostic Cardiovascular Imaging Research Laboratory, Department of Radiological Sciences, David Geffen School of Medicine at UCLA, 300 Medical Plaza, Suite B119, Los Angeles, CA 90095 (K.L.N., T.Y., P.H., J.P.F.); Division of Cardiology, David Geffen School of Medicine at UCLA and VA Greater Los Angeles Healthcare System, Los Angeles, Calif (K.L.N., N.K.); Department of Radiology (I.H.Z., M.R.B.), Center for Advanced Magnetic Resonance Development (I.H.Z., M.R.B.), and Division of Gastroenterology, Department of Medicine (M.R.B.), Duke University Medical Center, Durham, NC; Department of Diagnostic Radiology and Neurology, Oregon Health Sciences University, Portland, Ore (C.G.V.); British Heart Foundation Centre for Cardiovascular Science, University of Edinburgh, Edinburgh, Scotland (S.I.S., D.E.N.); Department of Imaging, Cedars-Sinai Medical Center, Los Angeles, Calif (R.S.); Department of Medical Imaging, Ann & Robert H. Lurie Children's Hospital of Chicago, Chicago, Ill (C.K.R., L.M.G.); Department of Radiology, Northwestern University Feinberg School of Medicine, Chicago, Ill (C.K.R., L.M.G.); Institute of Cardiovascular and Medical Sciences, University of Glasgow, Scotland (S.S., A.R.); Division of Cardiology, Department of Pediatrics and Radiology, Children's Hospital of Philadelphia, Philadelphia, Pa (K.K.W., M.A.F.); Department of Radiology, University of Wisconsin, Madison, Wis (L.M.G., M.L.S.); Department of Radiology, University of California, San Francisco and VA San Francisco Healthcare System, San Francisco, Calif (D.S., M.D.H.); Department of Radiology, Weill Medical College of Cornell University, New York, NY (M.R.P.); Department of Radiology, NHS Greater Glasgow and Clyde, and Institute of Cardiovascular and Medical Sciences, University of Glasgow, Glasgow, Scotland (G.H.R.); and Department of Neurology and Neurosurgery, Oregon Health Sciences University and VA Portland Healthcare System, Portland, Ore (E.A.N.). Received March 11, 2019; revision requested May 20; revision received August 1; accepted August 26. **Address correspondence** to K.L.N. (e-mail: klnuyen@ucla.edu).

The FeraSafe Multi-Center MRI Registry is hosted and supported by resources from the Department of Radiological Sciences, David Geffen School of Medicine, University of California, Los Angeles. REDCap is supported by the UCLA Clinical and Translational Science Institute (UL1TR001881). Investigators received grant support from the American Heart Association (18TPA34170049), British Heart Foundation (CH/09/002, RE/13/3/30183), British Heart Foundation Research Excellence Award (RE/13/5/30177), Chest Heart Stroke Scotland (A147), Medical Research Council of the National Institutes of Healthcare Research Efficacy and Mechanism Evaluation Program (11/20/03), National Institutes of Health (R01HL127153, 1R25EB016671, CA199111, CA137488, CA137488-1S1), National Cancer Institute (HHSN261200800001E), Veterans Administration MERIT Award (BX003897, CX001901), Walter S. and Lucieene Driskill Foundation, and a Wellcome Trust Senior Investigator Award (WT103782AIA).

Conflicts of interest are listed at the end of this article.

Radiology 2019; 293:554–564 • <https://doi.org/10.1148/radiol.2019190477> • Content code: **CA**

Background: Ferumoxytol is approved for use in the treatment of iron deficiency anemia, but it can serve as an alternative to gadolinium-based contrast agents. On the basis of postmarketing surveillance data, the Food and Drug Administration issued a black box warning regarding the risks of rare but serious acute hypersensitivity reactions during fast high-dose injection (510 mg iron in 17 seconds) for therapeutic use. Whereas single-center safety data for diagnostic use have been positive, multicenter data are lacking.

Purpose: To report multicenter safety data for off-label diagnostic ferumoxytol use.

Materials and Methods: The multicenter ferumoxytol MRI registry was established as an open-label nonrandomized surveillance data-bank without industry involvement. Each center monitored all ferumoxytol administrations, classified adverse events (AEs) using the National Cancer Institute Common Terminology Criteria for Adverse Events (grade 1–5), and assessed the relationship of AEs to ferumoxytol administration. AEs related to or possibly related to ferumoxytol injection were considered adverse reactions. The core laboratory adjudicated the AEs and classified them with the American College of Radiology (ACR) classification. Analysis of variance was used to compare vital signs.

Results: Between January 2003 and October 2018, 3215 patients (median age, 58 years; range, 1 day to 96 years; 1897 male patients) received 4240 ferumoxytol injections for MRI. Ferumoxytol dose ranged from 1 to 11 mg per kilogram of body weight (≤ 510 mg iron; rate ≤ 45 mg iron/sec). There were no systematic changes in vital signs after ferumoxytol administration ($P > .05$). No severe, life-threatening, or fatal AEs occurred. Eighty-three (1.9%) of 4240 AEs were related or possibly related to ferumoxytol infusions (75 mild [1.8%], eight moderate [0.2%]). Thirty-one AEs were classified as allergiclike reactions using ACR criteria but were consistent with minor infusion reactions observed with parenteral iron.

Conclusion: Diagnostic ferumoxytol use was well tolerated, associated with no serious adverse events, and implicated in few adverse reactions. Registry results indicate a positive safety profile for ferumoxytol use in MRI.

© RSNA, 2019

Online supplemental material is available for this article.

In the 30 years since gadolinium-based contrast agents (GBCAs) were first introduced to enhance MRI (1), their adoption into routine clinical practice has been prolific. Worldwide, more than 450 million doses of GBCAs have been administered and have yielded indispensable

diagnostic information in virtually every organ system (2). The safety profile of GBCAs was relatively unblemished until their association with nephrogenic systemic fibrosis in 2006 (3). Clinical practice patterns were altered rapidly, and judicious use or avoidance of GBCAs in patients with

Abbreviations

AE = adverse event, FDA = Food and Drug Administration, FE = ferumoxytol enhanced, GBCA = gadolinium-based contrast agent

Summary

Multicenter off-label experience in 4240 diagnostic ferumoxytol injections for MRI at nine sites in the United States and two sites in the United Kingdom showed no serious adverse events or adverse reactions in the setting of careful monitoring.

Key Results

- Multicenter observational registry safety experience in 3215 patients who underwent 4240 injections showed no systematic changes in vital signs after ferumoxytol administration ($P > .05$).
- No serious adverse events or adverse reactions occurred after off-label diagnostic use of ferumoxytol with MRI.
- The off-label diagnostic use of ferumoxytol was implicated in 83 acute adverse reactions (<2% of all injections), including hypertension, nausea, flushing, backache, pruritus, headache, and vomiting.

kidney disease has effectively eradicated nephrogenic systemic fibrosis. However, recent data supporting potential gadolinium retention have generated additional controversies surrounding the use of GBCAs in MRI (4). Central to these concerns is that gadolinium, a rare-earth metal, is not a normal constituent of biologic systems (1). The free gadolinium cation is toxic and highly reactive. When used in contrast agents, gadolinium is tightly chelated to prevent dissociation. It is unclear, however, whether this chelation is always effective for all agents; work is underway to determine the clinical consequences, if any, of long-term gadolinium retention in biologic tissues (2).

Meanwhile, interest in ferumoxytol (Feraheme; AMAG Pharmaceuticals, Waltham, Mass) as a contrast agent for MRI (5,6) has come full circle. Although ferumoxytol is approved in the United States and Europe for use in the intravenous treatment of iron deficiency anemia, it was originally designed as an injectable bolus blood pool contrast agent for MRI and has vascular imaging attributes that the other intravenous iron therapy products and the extracellular GBCAs do not possess (7,8). The dextran-derivative coating of ferumoxytol was designed to be nonreactive (less immunogenic, lower labile iron release) (7), and the particle size (30 nm or 750 kDa) is such that its affinity for macrophages is relatively low, leading to a long and stable intravascular residence time (5,8). Because of its long intravascular half-life (approximately 14–15 hours), unique MR relaxometry (r_1 , 23 L·mmol⁻¹ at 1.5 T [8]; r_1 , 9 L·mmol⁻¹ at 3.0 T [9]), and widespread use in chronic kidney disease, ferumoxytol has the potential to complement or serve as an alternative to GBCAs (5). It may also enable applications well beyond those possible with GBCAs (5,6). Since its clinical introduction in 2009, ferumoxytol has affected the practice of MRI at academic centers to fill a variety of unmet clinical needs when used off label (8–13).

In March 2015, on the basis of 79 reported instances of serious adverse events (AEs) that included 18 fatalities during the therapeutic use of ferumoxytol (of an estimated 1.2 million injections), the Food and Drug Administration (FDA) issued a black box warning (14) about potential acute hypersensitivity

reactions. The FDA identified bolus injection of undiluted ferumoxytol as a potential risk factor and issued updated therapeutic prescription recommendations that included dilution, infusion over 15 minutes (originally over 17 seconds), and hemodynamic monitoring for up to 30 minutes after infusion. Despite studies supporting innovative off-label theranostic applications (5,6,8–13) and single-center reports on safety (15–19), the relative safety of ferumoxytol for diagnostic use is still not well defined. Thus, we established the FeraSafe multicenter MRI registry (<https://ferasafe.ucla.edu>) as an academic collaboration to investigate the safety of ferumoxytol and to facilitate collaboration among users exploring its diagnostic applications. We aim to report the incidence of acute adverse events for diagnostic ferumoxytol injection and to describe the registry practice pattern for off-label use of ferumoxytol-enhanced (FE) MRI.

Materials and Methods

A detailed description of our method and the portion of patients ($n = 1774$) that overlaps with prior reports is listed in Appendix E1 (online). The local institutional review board at each site approved the contribution of deidentified data and waived specific written informed consent for retrospective inclusion into the FeraSafe registry. The FeraSafe registry was conducted without industry collaboration. The UCLA Clinical and Translational Science Institute and the Department of Radiological Sciences, David Geffen School of Medicine at UCLA provided infrastructure and resources.

Study Setting

This registry is an open-label, nonrandomized, multicenter phase IV surveillance databank with a consortium of nine U.S. and two U.K. urban academic medical centers. The primary exposure was FE MRI, and the primary outcomes were AEs. Each center had a site-specific safety monitoring protocol and personnel familiar with the diagnosis and treatment of hypersensitivity reactions, and therapy was available for immediate response. Cross-sectional safety data from all consecutive patients who underwent FE MRI were prospectively collected at each center and were retrospectively recorded in the registry.

Registry Design, Data Elements, and Safety Outcomes

The FeraSafe multicenter MRI registry is cloud based and operates using an open-source REDCap platform (version 8.5.28; Vanderbilt University, Nashville, Tenn) (20) for data collection and curation. Data elements include type of diagnostic MRI examination, region of imaging, patient characteristics, clinical indication, ferumoxytol administration (dose [milligrams of iron per kilogram of body weight], rate [milligrams of iron per second]), vital signs, safety personnel, and AEs. A detailed description of safety monitoring is provided in Appendix E1 (online). Safety data for FE MRI examinations between January 2003 and October 2018 were included in the analysis. Each site defined severity of AEs according to the National Cancer Institute Common Terminology Criteria for Adverse Events (version 4.0) (21) and classified AEs as unrelated, possibly related, or definitely related to ferumoxytol administration. To maintain consistency with the American College of Radiology Manual on

Contrast Media (22), the FeraSafe registry core laboratory reviewed all AEs (K.L.N., a board-certified cardiologist with >10 years of experience in critical care and >13 years of experience with intravenous iron compounds and management of allergic reactions; J.P.F., a board-certified radiologist with >30 years of experience with MRI contrast agent reactions) and classified (K.L.N.) them according to the American College of Radiology Contrast Media Classification System. The core laboratory (K.L.N.) also classified AEs by using consensus definitions from the Kidney Disease Improving Global Outcomes conference (23). A summary is provided in Table E1 (online). When available, mean arterial pressure, heart rate, and pulse oximetry before and after infusion were collected (K.L.N., N.K., T.Y.) from each site. Anaphylactic reactions were defined as symptoms involving multiple organ systems (skin, gut, respiratory, cardiovascular), along with objective findings of bronchoconstriction, stridor, refractory hypotension, severe generalized urticaria, nausea, and abdominal pain (23). Minor infusion reactions were those with nonspecific symptoms, including pressure or discomfort in the chest or lumbar area associated with flushing, with or without minor urticaria, and without refractory hypotension or other organ involvement (23).

Statistical Analysis

We summarized the data as mean \pm standard deviation, median, and interquartile range, or as an absolute value and a frequency, as appropriate. We performed group comparisons of vital signs by using analysis of variance. We considered $P < .05$ to indicate a significant difference. We used MedCalc, version 16.8.4 (Ostend, Belgium) software to perform the statistical analysis.

Results

The multicenter MRI registry has 11 partner institutions. Patient demographics are summarized in Table 1. Between January 2003 and October 2018, a total of 3215 patients (59% [$n = 1897$] male, 41% [$n = 1318$] female; median age, 58 years; age range, 1 day to 96 years) across nine academic medical centers in the United States and two in the United Kingdom received 4240 ferumoxytol injections for MRI purposes. Of these 3215 patients, 887 (28%) had formally recorded vital signs. More adults (87%, 2807 of 3215) than children (age ≤ 18 years) (13% [409 of 3215]; 72% [296 of 409] of children were anesthetized) received ferumoxytol. A total of 148 patients (4.6%) had immature renal function (age < 3.5 years). In 1107 patients with a recorded serum creatinine value, the range was 0.2–28.0 mg/dL (15.25–2135 $\mu\text{mol/L}$) (median, 1.2 mg/dL [91.5 $\mu\text{mol/L}$]; interquartile range, 0.8–2.7 mg/dL [61–205.9 $\mu\text{mol/L}$]).

Practice of FE MRI

Diagnostic imaging use of ferumoxytol differs from therapeutic use in two important ways: (a) it has a lower total iron dose with dilution and (b) it has a lower average injection rate. Both early and late phases of ferumoxytol biodistribution (Fig 1) were employed in a wide range of MRI applications. Illustrative examples of FE MRI applications are shown in Figures 2 and 3. Study indications are shown in Figure 4 and include

Table 1: Patient Characteristics

Characteristic	No. of Patients ($n = 3215$)
Age*	
Neonates (≤ 1 month)	45 (1.4)
Infants (1 month to ≤ 2 years)	71 (2.2)
Children (2 years to ≤ 12 years)	151 (4.7)
Adolescents (12 years to ≤ 16 years)	44 (1.4)
Young adults (16 years to ≤ 39 years)	353 (11.0)
Middle-aged adults (39 years to ≤ 65 years)	1442 (44.9)
Older adults (> 65 years)	958 (29.8)
Sex	
Male	1897 (59)
Female	1318 (41)

Note.—Data in parentheses are percentages. In 151 (4.7%) patients, age was not recorded.

* Median age was 58 years (interquartile range, 40–67 years; range, 1 day to 96 years).

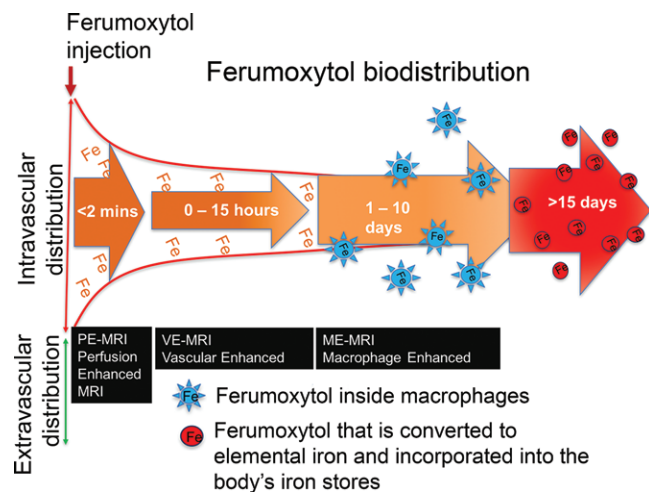


Figure 1: Ferumoxytol biodistribution and diagnostic applications in MRI. Ferumoxytol preferentially enhances the intravascular space compared with other tissue compartments at less than 15 hours.

healthy volunteers, outpatients, and inpatients. Common indications included vascular, liver, and tumor imaging and evaluation of congenital heart disease. Historical practice patterns by registry partners are reported in Table 2 and have evolved since the FDA warning. Physicians did not routinely monitor renal function beyond routine clinical care because ferumoxytol is metabolized by macrophages and incorporated into the reticuloendothelial system rather than through renal excretion. For diagnostic MRI, the total amount of iron used was no more than half the therapeutic dose. Prior to 2015, both weight-based (1–11 mg iron/kg) and non-weight-based dosing (≤ 510 mg iron) of ferumoxytol were used. The dilution factor ranged from 1:1 to 1:10. The maximum infusion rate was 45 mg iron/sec, but more frequently, the rate was 30 mg iron/sec or less for first-pass imaging indications, followed by steady-state image acquisition. After 2015, infusion rates were typically less than 0.6–10.0 mg iron/sec. For indications where a

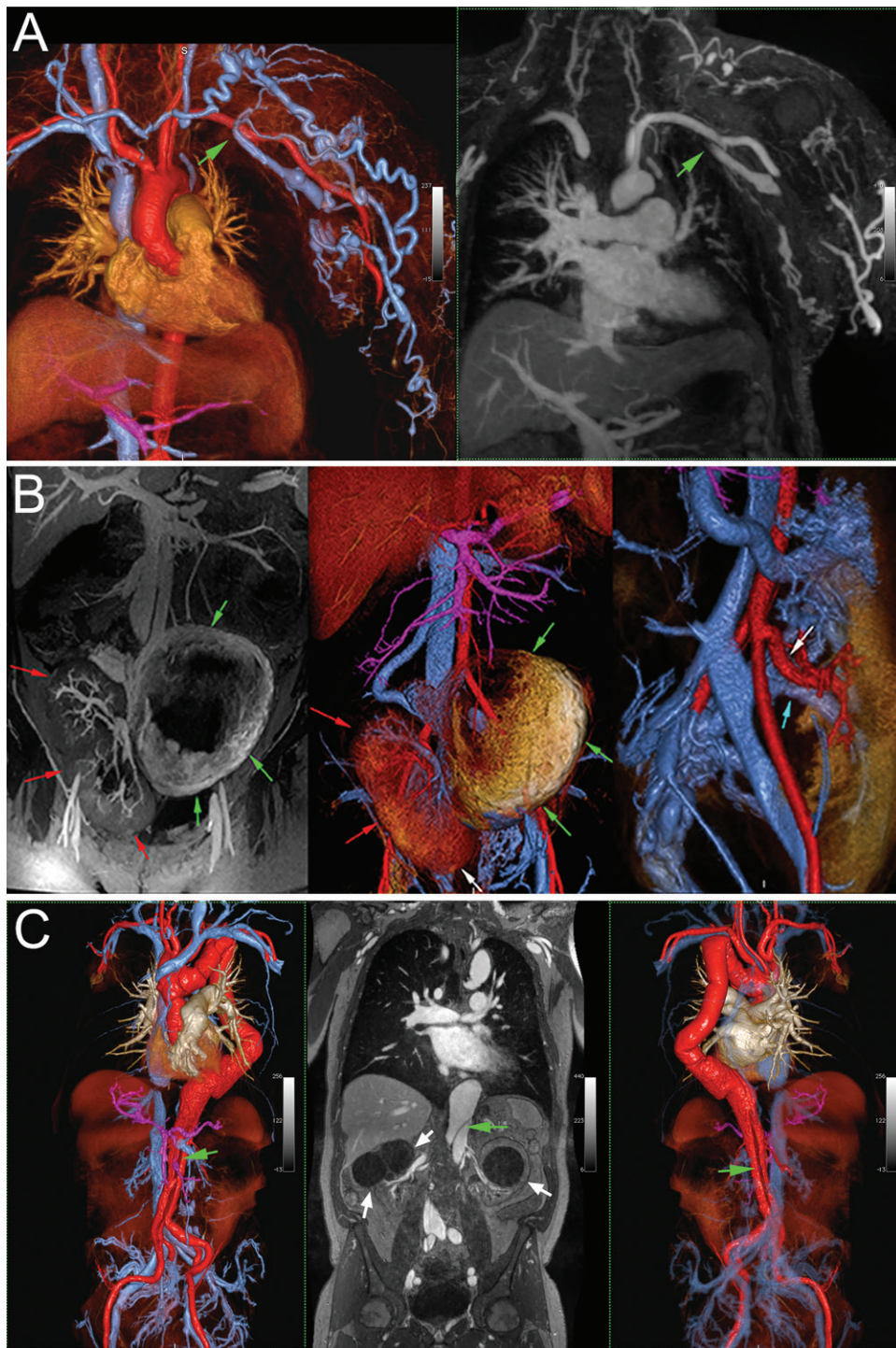


Figure 2: Sample illustrative images obtained with ferumoxytol-enhanced (FE) MRI, with maximum intensity projection (MIP) and color volume-rendered (VR) reconstructions. Examples include, A, venography in a 70-year-old man with a left subclavian vein occlusion (green arrow) (left panel, VR FE MRI; right panel, MIP reformatted MRI) and, B, uteroplacental imaging (normal uteroplacental enhancement [left and middle panels, green arrows] and perfusion from the uteroplacental arterial [right and middle panels, white arrow] and venous [right panel, blue arrow] network and a healthy right pelvic renal transplant [left and middle panels, red arrows]) in a 26-year-old woman who delivered a healthy baby. C, Multistation MR angiogram in a 69-year-old man with chronic aortic dissection (dissection flap; left and right panels, green arrow) and chronic renal failure. Note the bilateral renal cysts in the middle panel (white arrows). Extensive surgical aortic reconstruction has been performed in the thorax.

higher rate was used, diluted ferumoxytol was administered in a controlled fashion by using infusion pumps and as multiple small divided doses over a total duration of more than 15 min-

utes. For clinical use, the safety monitoring personnel during ferumoxytol administration included attending physicians, nurses, and technologists. At all times, a physician was within close proximity to the imaging location, and standard resuscitation equipment was available. For research use, the safety monitoring personnel frequently comprised the physician investigator or study nurse with clinical expertise in managing hypersensitivity reactions and experience managing contrast material-related reactions. Written informed consent for clinical administration of ferumoxytol varied according to local institutional requirements. MRI (62%, 2629 of 4240), MR angiography (20%, 848 of 4240), or both (18%, 763 of 4240) were performed. Both single- and multistation MRI examinations were performed. Most examinations were performed without anesthesia or sedation (91%, 3858 of 4240).

Hemodynamic Analysis

For patients with formally recorded vital signs ($n = 887$), changes in heart rate, mean arterial pressure (MAP) ($MAP = \frac{(2 \cdot BP_{dis}) + BP_{sys}}{3}$),

where BP_{dis} is diastolic blood pressure and BP_{sys} is systolic blood pressure, and oxygen saturation are summarized in Figure 5. Mean arterial pressure reflects the time-weighted average of blood pressure within a cardiac cycle and is used for comparison because mean arterial pressure better reflects tissue perfusion than does systolic blood pressure by accounting for two-thirds of the cardiac cycle spent in diastole. There was no systematic change in heart rate or mean arterial pressure

after ferumoxytol injection ($P > .05$). Minor postinfusion differences in heart rate and mean arterial pressure were not significant, regardless of infusion rate (>10 mg iron/sec vs <10

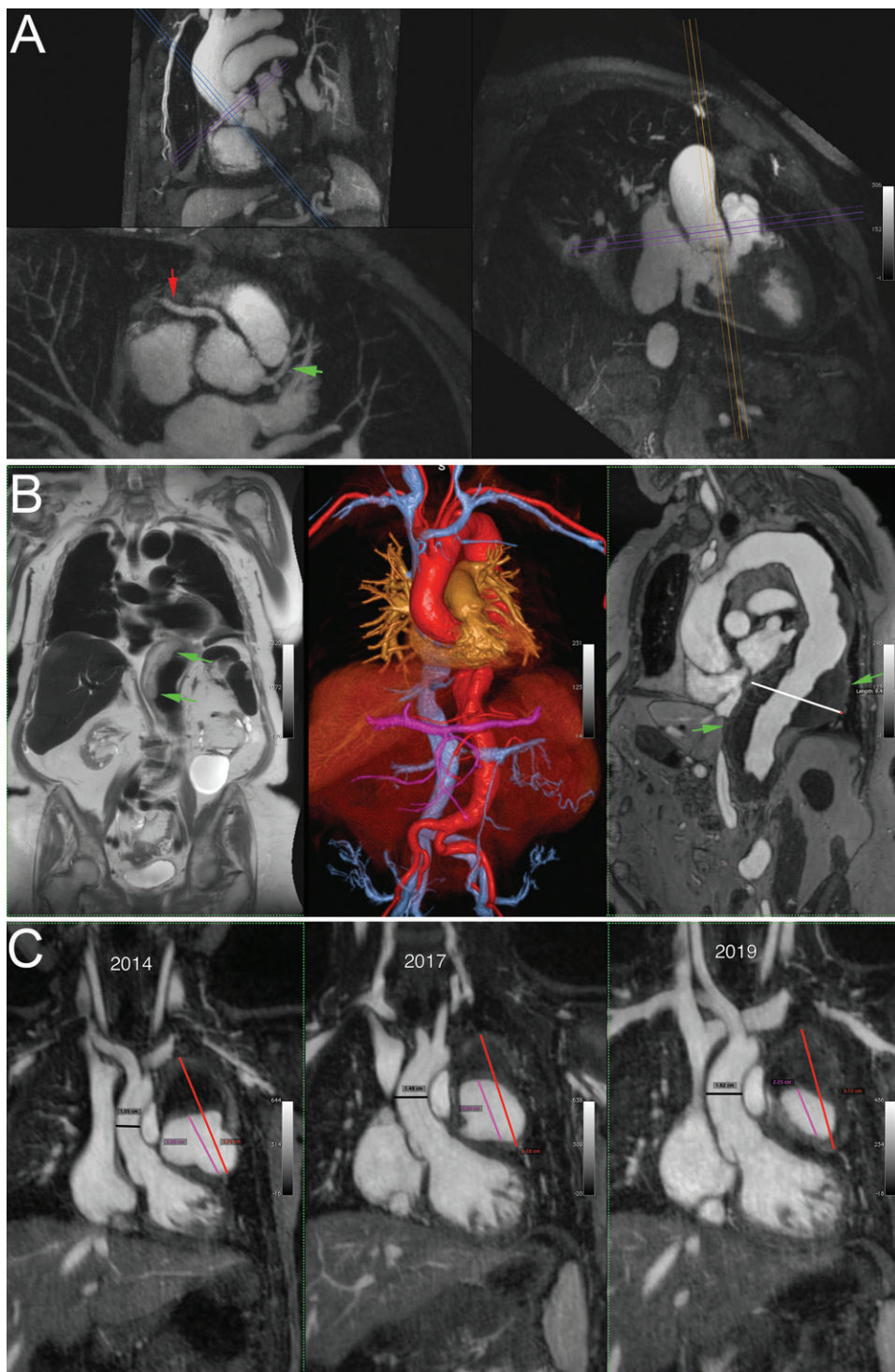


Figure 3: A, Coronary images in an 87-year-old male patient prior to transcatheter aortic valve replacement (maximum intensity projection showing the height of the coronary takeoff [upper panel], the ostium, and proximal segments of the right coronary artery [lower panel, red arrow] and left coronary artery [lower panel, green arrow], and an oblique view of the aortic root in relation to other vessels). B, Vascular mapping with complementary ferumoxytol-enhanced black-blood (left panel), color three-dimensional volume-rendered reconstruction (middle panel), and bright-blood (right panel) MRI techniques in an 83-year-old woman with a partially thrombosed (green arrows) 9.4-cm thoracoabdominal aneurysm. C, Sample images over a 5-year span in a girl with Kawasaki disease who was examined annually since presentation at 15 months of age. Note progressive thrombosis of the left main coronary artery aneurysm from 2014 (left panel) to 2017 (middle panel) to 2019 (right panel). The progressively narrowed vascular lumen of the aneurysm (pink line in the left, middle, and right panels) is accompanied by a relatively stable overall aneurysm size (red line in the left, middle, and right panels).

mg iron/sec). Three (0.3%) of 887 patients had objective instances of hypotension.

Adverse Reactions

No ferumoxytol-related severe or life-threatening AEs occurred. No deaths related to diagnostic use of ferumoxytol were reported. A summary of common infusion reactions experienced with diagnostic ferumoxytol injections compared with commercially available macrocyclic GBCAs is provided in Table 3. A total of 83 AEs (1.9% [83 of 4240]) were possibly or definitely related to ferumoxytol administration and were considered adverse reactions (75 mild [1.8%] and eight moderate [0.2%] based on the National Cancer Institute Common Terminology Criteria for Adverse Events). When we used the American College of Radiology classification system, 52 symptoms fell into the physiologic reactions category (all 52 were mild), and 31 fell into the allergiclike category (23 were mild, eight were moderate). All 31 allergiclike symptoms met the Kidney Disease Improving Global Outcomes criteria for expected minor infusion reactions; none met the criteria or had objective findings to be considered anaphylactic reactions. On a per-patient basis, 69 patients developed adverse reactions. Six patients (two children) received supportive care (patients 1–6 [Table 4]). Three of the 69 patients had symptoms characteristic of parenteral iron infusion (Table 4), which have been previously described as Fishbane reactions (24). The symptoms were self limited and resolved after termination of ferumoxytol infusion, and the patients did not receive any medical treatment. Fishbane reaction refers to a constellation of symptoms

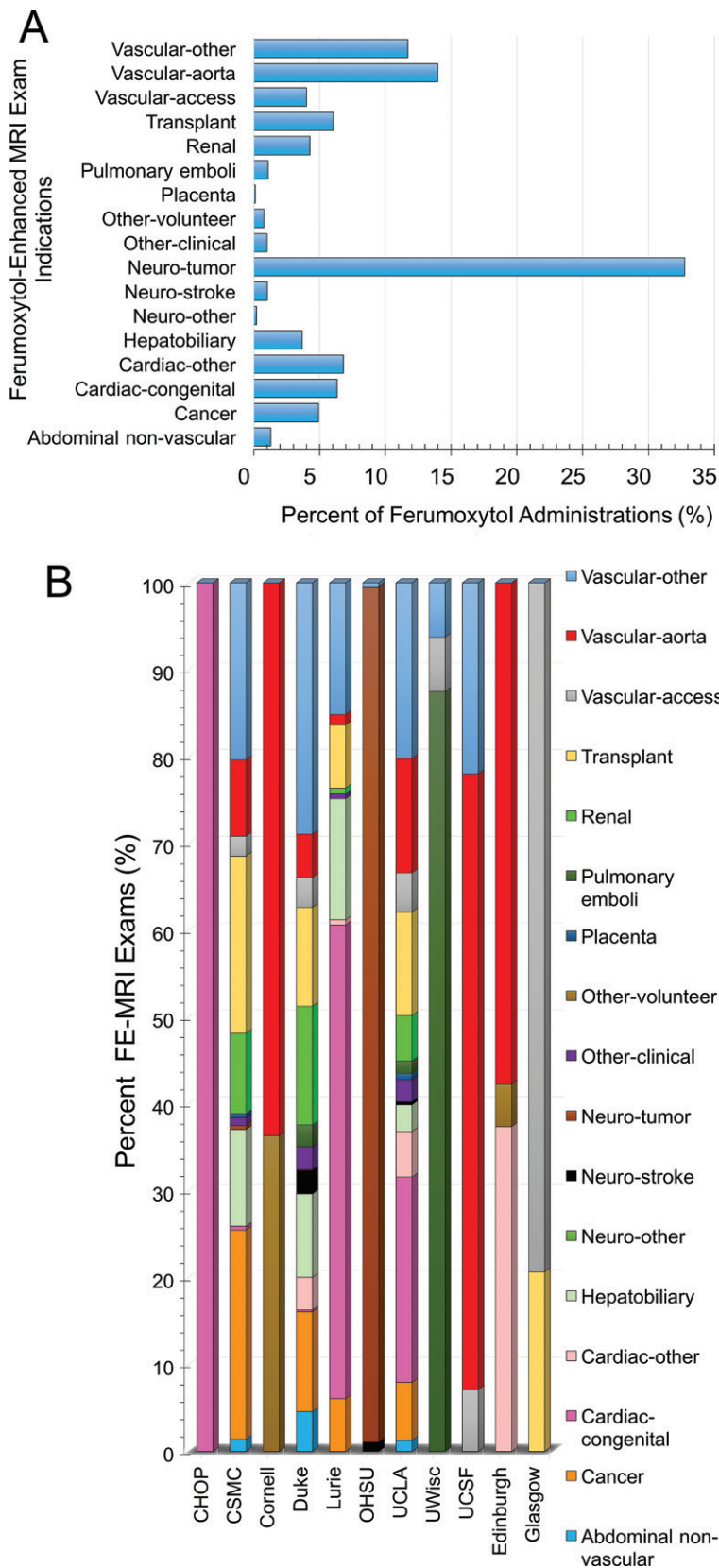


Figure 4: Spectrum of clinical and research ferumoxytol-enhanced (FE) MRI. A, Graph of first-pass and steady-state FE MRI for a wide spectrum of indications (n = 4240). B, Graph shows the spectrum of clinical and research applications varied by institution. Three centers (Duke, UCLA, and CSMC) had the widest spectrum of clinical indications. CSMC = Cedars-Sinai Medical Center; CHOP = Children's Hospital of Philadelphia; OHSU = Oregon Health State University; UCLA = University of California, Los Angeles; UCSF = University of California, San Francisco; UWisc = University of Wisconsin.

(acute myalgias, arthralgias, headache, chest pressure, and/or back pain, without clinical findings of wheezing, stridor, periorbital edema, or persistent hypotension) associated with intravenous iron infusions. Two patients in the moderate category (Table 4, patients 5 and 6) were treated with medical therapy, but their symptoms may have been manifestations of Fishbane reaction. No adverse reactions were reported in 296 anesthetized children receiving diluted ferumoxytol infusion for MRI (infusion rate range of 0.01–0.25 times lower than the previously approved maximum rate for therapeutic use).

Discussion

Multicenter registry experience for off-label diagnostic use of ferumoxytol among nine U.S. and two U.K. sites showed no serious adverse events (AEs) or serious adverse reactions in the setting of careful monitoring. Practice patterns for ferumoxytol-enhanced (FE) MRI varied. Minor infusion reactions were expected, but the incidence was rare (<2%). Hypotension occurred in three patients; however, none of these incidents were serious. In patients in whom reactions were mild, the presence of symptoms did not always preclude completion of the examination. Compared with the published rate of severe immediate allergiclike reactions to gadolinium-based contrast agent (GBCA) injections (overall rate of 0.52 per 10 000 injections of a gadolinium chelate [25]; rate of 8.3 per 10 000 injections for linear ionic GBCAs, and rate of 16 per 10 000 injections for nonionic macrocyclic GBCAs), our interim data suggest a lower rate for ferumoxytol. Our registry data for diagnostic ferumoxytol use differ from the post-marketing surveillance data for therapeutic use in three important ways: (a) lower total ferumoxytol dose, (b) slower average infusion rate, and (c) careful monitoring during and after administration.

To date, experience with older formulations of parenteral iron and iron-based MRI contrast agents (26) continue to cast a shadow over the newer agents, despite the rarity of serious adverse reactions (<1:200 000 injections) (23). Compared with the published incidence of back pain associated with older iron-based MRI contrast agents (26) and ferumoxytol therapeutic infusions (23), the incidence of back pain during diagnostic ferumoxytol use was lower (0.05% [two of 4240 injections]). Our multicenter safety data enable us to confirm the low incidence of adverse reactions reported in single-center diagnostic safety reports (15–19). More recent safety data (23,27) for therapeutic ferumoxytol applications are available, but they have not fully quelled safety concerns. Although ferumoxytol was designed to be less immunogenic

Table 2: Summary of Multicenter FE MRI Practice Pattern

Variable	U.S. Site									U.K. Site	
	1	2	3	4	5	6	7	8	9	1	2
Type of FE MRI	Clinical, research	Clinical	Research	Clinical, research	Clinical	Research	Clinical, research	Clinical, research	Clinical, research	Research	Research
Dilution factor, final volume	1:4	1:4	No dilution, multi-dose	1:5; final volume, 30 mL	Final volume, 60 mL	1:1–1:2	1:4–1:10; final volume, 60 mL	Final volume, 30–60 mL	1:4	Final vol-1:4	Final vol-1:4
Total dose (mg iron/kg)*	4	4	4	3	2–3	2–11	4	3	1.2–5	4	3
Historical rate (mg iron/sec)*	<0.6	<0.6–30	30	6–30	<0.6	<0.6–45	<15	<0.6	<30	<0.6	<0.6–6
Current rate (mg iron/sec)*	<0.6	<0.6	...	6	<0.6	1–45	<0.6–6	<0.6	<0.6	<0.6	6
Consent†	Yes	No	Yes	No (clinical)	No	Yes	Yes	Yes	Yes	Yes	Yes
Monitoring personnel	MD	T	MD	RN	MD	MD or RN	MD	RN	RN	MD	MD
Iron studies‡	No	Yes	No	No	No	No	Selective	No	No	No	No
Other monitoring	No	No	No	No	No	No	No	No	No	No	Alert card
Setting	IP	IP, OP (hospital)	OP	IP, OP	IP, OP (hospital)	OP	IP, OP (hospital)	IP, OP (hospital)	IP, OP (hospital)	OP	IP, OP

Note.—A total of 4240 injections were performed in 3215 patients. FE = ferumoxytol enhanced, IP = in-patient, MD = physician, OP = outpatient, RN = registered nurse, T = technologist.

* Total ferumoxytol dose did not exceed 510 mg of iron. Ferumoxytol rate is expressed as milligrams of iron per second to minimize confusion among arbitrary use of the terms *bolus*, *fractionated*, *rapid*, *fast*, and *slow* infusion. For an infusion rate of 45 mg iron/sec or 30 mg iron/sec, injections were administered in a controlled fashion by using infusion pumps and as multiple small divided doses (mg iron/kg) over a total duration longer than 15 minutes. A ferumoxytol volume calculator is available at <https://www.radiology.wisc.edu/algad-calc>.

† Consent refers to written informed consent for ferumoxytol use. Clinical consent for FE MRI varied depending on local institutional requirements.

‡ Iron studies (serum iron, ferritin, transferrin, total iron-binding capacity, hemoglobin) were checked by referring physicians in select patient populations.

(7,28), in some patients, the labile free iron release can cause a Fishbane reaction, which has a benign course. The published frequency of these symptoms ranges from 1% to 3% (29), whereas our experience indicates a frequency of 0.1% (three likely instances and two probable instances out of 4240 injections).

Since earlier reports of spontaneous AEs to the FDA Adverse Event Reporting System, no further fatal events have arisen. For therapeutic ferumoxytol use, one laboratory-proven case of anaphylactic reaction in a 77-year-old woman with chronic kidney disease and prior allergies to iron dextran has been described (30). For diagnostic ferumoxytol use, one case of possible anaphylaxis that involved a child who underwent FE MRI under general anesthesia and developed hypotension but completed the examination has been described (19). These findings are reassuring when compared with the FDA postmarketing surveillance data. Due to the nature of AE self-reporting, postmarketing safety signals can result in overly cautious conclusions, partly due to the Weber effect (31). Importantly, challenges, including lack of standardization in hypersensitivity

nomenclature and unreliable diagnostic tools for hypersensitivity reactions, also limit the accounting of true immunoglobulin E-mediated events.

Although longer-term results are needed, several comments can be made based on our multicenter registry findings. In patients with impaired renal function or allergic reactions to GBCAs and in those needing multiple intravenous contrast-enhanced MRI examinations, the benefits relative to the risks of ferumoxytol versus GBCAs merit close consideration. In patients with complex or extensive vascular disease, the imaging properties of ferumoxytol may offer definite advantages over extracellular GBCAs. Dosing and infusion rates require patient-specific adjustment depending on the clinical indication. Dilution and monitoring of vital signs are recommended by the FDA. The ability of users to differentiate minor infusion reactions from severe immune-mediated allergic reactions is highly important. Users need to recognize Fishbane reactions and treat them as self-limited reactions with discontinuation of the infusion, watchful monitoring, and—in patients with refractory

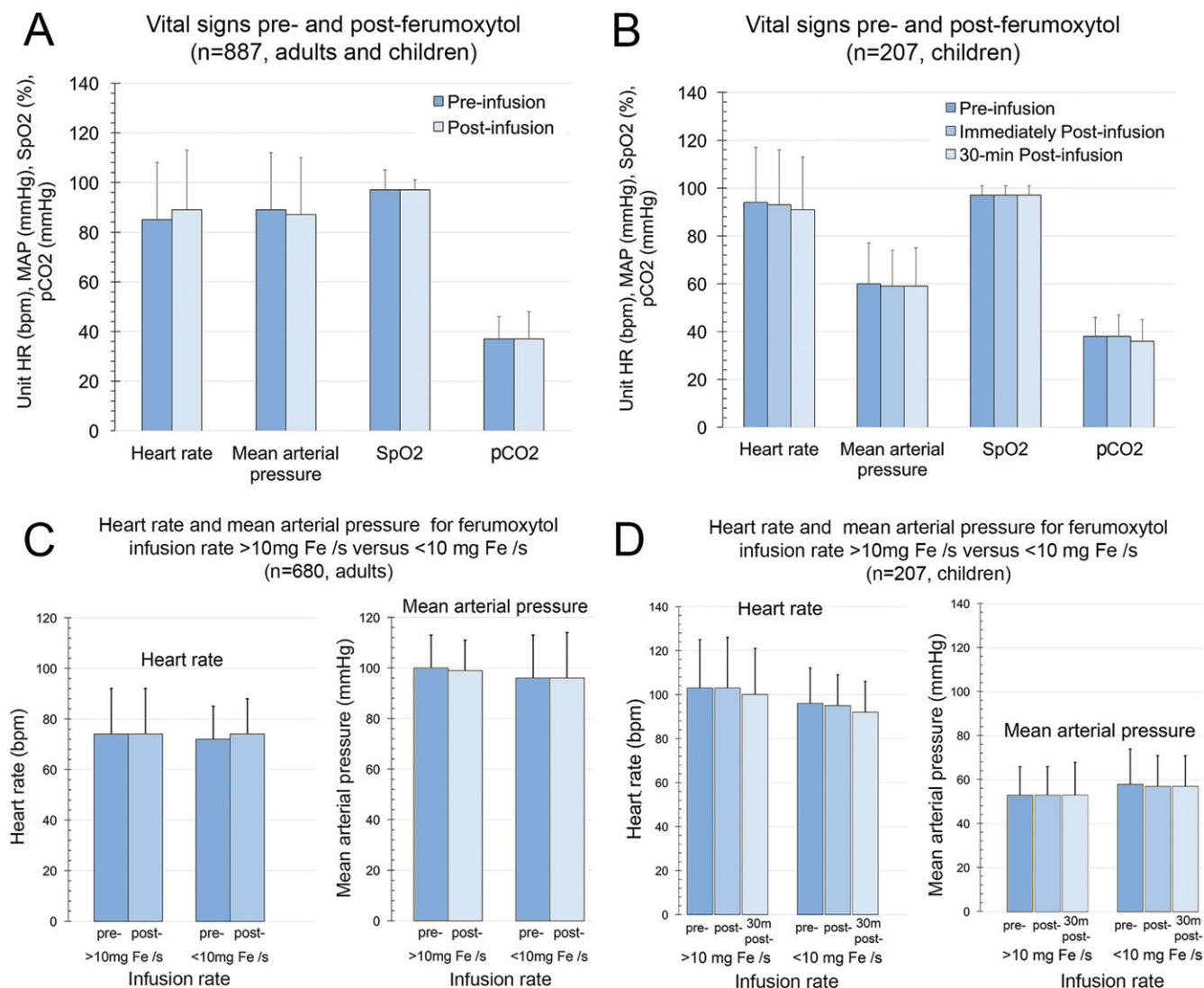


Figure 5: Pre- and postferumoxytol infusion vital signs for ferumoxytol-enhanced (FE) MRI. A, There was no significant systematic difference between pre- and postinfusion vital signs across a wide age spectrum (887 patients, $P = .42$). B, In children (age < 18 years), differences between pre- and postinfusion vital signs were also not significant (207 patients, $P = .50$). No significant differences in heart rate (HR) or mean arterial pressure (MAP) were observed with an infusion rate of more than 10 mg iron/sec or less than 10 mg iron/sec for both, C, adults (680 patients, $P = .99$) and, D, children (207 patients, $P = .89$). Analysis of variance was used for group comparisons. pCO₂ = partial pressure of carbon dioxide, SpO₂ = peripheral capillary oxygen saturation.

symptoms—supportive care (23). Misinterpretation of minor infusion reactions for true hypersensitivity reactions may lead to reflexive use of diphenhydramine (a sedating antihistamine), steroids, inotropes, vasopressors, or a combination thereof, which could cause or potentiate adverse effects (29,32).

Our study had limitations. Because registry data reflect pragmatic experience, clinical trials criteria are less applicable and reporting efforts by collaborating sites were voluntary. Because of the rarity of serious immune-mediated allergic reactions, our current sample size is not sufficiently powered to evaluate the relationship between injection rate and serious adverse reactions. On the basis of our cohort, the incidence of adverse reactions should be no higher than 2% at the lower range of injection rates. We used a published serious hypersensitivity rate of 0.2%–0.9% from therapeutic administrations (33) and expected two to 10 events per 1000 injections, but no anaphylaxis or serious reactions were reported in our

registry. Although there is potential for AE reporting biases, the absence of serious AEs supports further prospective investigations. A consistent definition of anaphylactic reactions among society guidelines was also lacking. Classification of symptoms into “minor infusion reactions” versus “anaphylactic reactions” based on the Kidney Disease Improving Global Outcomes (23) summary was useful for defining the subsequent management plan. Only 28% (887 of 3215) of patients in our registry had vital signs formally recorded, but in the remainder, no symptoms of hypotension were reported. We defined hypotension as symptomatic hypotension or a decrease in mean arterial pressure below the threshold required for perfusion (ie, mean arterial pressure < 65 mmHg in adults [34]). Finally, systematic monitoring for iron overload was not performed. However, from a pragmatic standpoint, iron deficiency, largely related to blood loss (23,35), is far more common than iron overload.

Table 3: Frequency of Adverse Reactions for Ferumoxytol Relative to Clinically Available Macrocytic Gadolinium-based Contrast Agents

Adverse Reaction	Ferumoxytol (Feraheme)		Gadobutrol (Gadavist)	Gadoterate (Dotarem)	Gadoteridol (ProHance) 2013
	Therapeutic 2018 Insert* (n = 997)	Diagnostic Registry Data (n = 3215)	2011 Insert*	2013 Insert*	Insert*
			Diagnostic (n = 4549)	Diagnostic (n = 2813)	Diagnostic (n = 1251)
Nausea	18 (1.8)	9 (0.3)	55 (1.2)	16 (0.6)	17 (1.4)
Vomiting	...	7 (0.2)	18 (0.4)	<5 (<0.2)	12 (<1)
Headache	34 (3.4)	8 (0.3)	68 (1.5)	14 (0.5)	12 (<1)
Hypertension	...	10 (0.3) [†]	...	<5 (<0.2)	12 (<1)
Hyperglycemia	...	2 (0.1) [†]
Pruritus	...	9 (0.3)	9 (0.2)	<5 (<0.2)	12 (<1)
Chest pressure	2 (0.2)	6 (0.2)
Hypotension	...	7 (0.2) [‡]
Flushing	2 (0.2)	3 (<0.1)	<4 (<0.1)	...	12 (<1)
Rash	...	3 (<0.1)	13 (0.3)	<5 (<0.2)	12 (<1)
Back pain	10 (1.0)	2 (<0.1)
Discomfort	...	2 (<0.1)
Dyspnea	3 (0.3)	2 (<0.1)	9 (0.2)	...	12 (<1)
Ocular hyperemia	...	2 (<0.1)
Sneezing	...	2 (<0.1)
Tachycardia	...	1 (<0.1) [†]	<4 (<0.1)	...	12 (<1)
Dysgeusia	...	2 (<0.1)	22 (0.5)
Paresthesia	...	1 (<0.1)	4 (0.1)	<5 (<0.2)	12 (<1)
Dizziness	15 (1.5)	1 (<0.1)	18 (0.4)	<5 (<0.2)	12 (<1)
Miscellaneous	...	4 (0.1)
Anaphylactoid reactions	Reported	None	Reported	Reported	Reported
Cardiac arrest	Reported	None	Reported	Reported	Reported
Nephrogenic systemic fibrosis	Reported	Reported (confounded)	Not reported

Note.—Data in parentheses are percentages. Manufacturers for agents listed in the table are as follow: ferumoxytol (AMAG Pharmaceuticals, Waltham, Mass), gadobutrol (Bayer, Whippany, NJ), gadoterate (Guerbet, Princeton, NJ), and gadoteridol (Bracco, Monroe Township, NJ).

* Adverse reactions from inserts refer to those reported in the package insert for each contrast agent.

[†] Symptoms were recorded, but corresponding blood pressure, blood glucose level, and heart rate were not available for adjudication.

[‡] Mean arterial pressure was available in three instances to support hypotension.

The potential disadvantages of ferumoxytol merit mention. Its long intravascular half-life may influence the MRI signal for days (or weeks to months in some organs depending on the imaging sequences used) after administration and may confound interpretation of MRI findings by inexperienced radiologists. Once aware of expected changes, radiologists can learn to interpret the images in context and without confusion. In the steady state, ferumoxytol enhances arteries and veins equally and independently of bolus timing. While this attribute can simplify vascular imaging of the chest, abdomen, and pelvis (where arteries and veins are readily distinguishable based on anatomy), this is not the case in the brain and extremities, and alternative approaches will be required for efficient separation of arteries and veins.

Cost is an important consideration with any diagnostic agent, and the commercial landscape surrounding the diagnostic use of ferumoxytol is complicated. Although approved in the United States and Europe to treat iron deficiency anemia, ferumoxytol

is only commercially available in the United States at this time and is marketed as a single-dose 17-mL vial (510 mg of iron). Ferumoxytol is priced as a therapeutic agent, and its typical price point (approximately \$700 per 17-mL vial) is not realistic for an MRI contrast agent (other than for very limited applications). The per-vial cost varies substantially and does not account for intangible benefits that may outweigh the monetary cost. A further complication is the fact that the typical dose used for diagnostic imaging is less than a full vial, and any unused product must be discarded. Some partner institutions in our registry have sought assistance from in-house pharmacies to provide smaller aliquots for same-day multipatient diagnostic use. Interestingly, one site had several patients who were already on an intravenous iron regimen and who, in coordination with their physicians, requested that the remaining dose of ferumoxytol be administered on completion of the MRI study.

In conclusion, off-label use experience from our multi-center registry points to a positive safety profile for ferumoxytol

Table 4: Summary of Patients with Grade 2 Adverse Reactions and Patients with Possible Fishbane Reactions

Patient No./ Sex/Age (y)	Medical History	Infusion Reaction	Intervention	Sequelae
Patients Who Received Supportive Intervention (Grade 2, Moderate Severity)				
1/F/15	Postrenal transplant, allograft failure, and cardiomyopathy; FE MRI to evaluate abdominal-pelvic vessels	Developed pruritus of the nose and a ticklish cough within 5 minutes of slow ferumoxytol infusion; no skin rash, urticaria, or wheezing; vital signs were stable	Diphenhydramine, 1 mg/kg	None
2/F/30	Pregnant with chronic hypotension, tachycardia, and shortness of breath; FE MRI to exclude pulmonary emboli	Felt faint after slow ferumoxytol infusion; initial MAP, 60 mmHg	Intravenous fluids, 500 mL	Symptoms resolved; Repeat MAP, 92 mmHg
3/M/65	Glioblastoma	Truncal rash appeared shortly after ferumoxytol infusion	Dexamethasone	Rash resolved after several hours
4/M/66	Glioblastoma	Developed red sclera and burning-tingling sensation at initial infusion; at second injection 6 months later, patient developed nausea, shortness of breath, and lower back pain after ferumoxytol infusion (1 mg/kg)	Albuterol and diphenhydramine were administered at the second injection	All symptoms resolved within 2 hours of treatment
5/M/26*	Double outlet right ventricle with lateral Fontan procedure, on dialysis; FE MRI to evaluate Fontan procedure outcome	Developed stomach pain, headache, and emesis accompanied by transient hypotension (an MAP decrease from 76 mmHg to 50 mmHg)	Intravenous fluids	All symptoms resolved
6/M/8*	Abdominal aortic aneurysm, history of eczema and food allergy; FE MRI to evaluate vascular anomaly	Reported pruritis during infusion; examination showed hives with development of vomiting and chest pain; imaging was terminated; vital signs were unchanged	Diphenhydramine (1 mg/kg), solumedrol, Zantac; sent to emergency department	Discharged home with steroid taper, diphenhydramine, and Zantac for 3 days
Patients with Symptoms Suggestive of Fishbane Reaction				
7/F/30	Repaired tetralogy of Fallot; FE MRI to evaluate RV volumetry	Developed symptoms of flushing, nausea, and back pain during infusion; vital signs were stable	Ferumoxytol infusion was terminated	None
8/F/19	Postrenal transplantation; FE MRI was performed to evaluate a mass on the tricuspid annulus	Developed flushing and chest tightness during infusion	Ferumoxytol infusion was terminated	None
9/M/11	Interrupted inferior vena cava; FE MRI was performed to exclude heterotaxy	Experienced nausea, vomiting, and flushing; vital signs were stable	Ferumoxytol infusion was terminated	None

Note.—FE = ferumoxytol enhanced, MAP = mean arterial pressure, RV = right ventricle.

* Likely Fishbane reaction.

injections in MRI, with a very low incidence of adverse reactions (<2%). Across a wide range of age, applications, and injection rates in patients with chronic kidney disease, ferumoxytol holds promise as a safe alternative or complement to existing gadolinium-based contrast agents and extends MRI applications beyond their current bounds. To date, and to our knowledge, no clinical trials have been performed to directly address the safety of ferumoxytol as an MRI contrast agent, but full clinical development to establish labeled diagnostic indications may be warranted. Meanwhile, an expanding registry databank will further support convergence toward a confident and precise assessment of adverse reaction rates in diagnostic practice.

Acknowledgments: The authors are grateful to attendees at the Ferumoxytol Working Group meetings in Toronto, Ontario, Canada (International Magnetic Resonance in Medicine, 2015 Annual Meeting), and Paris, France (International Magnetic Resonance in Medicine, 2018 Annual Meeting), for helpful discussions.

Author contributions: Guarantors of integrity of entire study, K.L.N., I.H.Z., R.S., J.P.F.; study concepts/study design or data acquisition or data analysis/interpretation, all authors; manuscript drafting or manuscript revision for important intellectual content, all authors; approval of final version of submitted manuscript, all authors; agrees to ensure any questions related to the work are appropriately resolved, all authors; literature research, K.L.N., N.K.P., I.H.Z., S.S., D.S., M.D.H., M.R.P., A.R., E.A.N., J.P.F.; clinical studies, K.L.N., T.Y., I.H.Z., C.G.V., S.I.S., R.S., C.K.R., S.S., K.K.W., D.S., M.D.H., M.A.F., M.L.S., G.H.R., A.R., D.E.N., E.A.N., M.R.B., P.H., J.P.F.; statistical analysis, K.L.N., T.Y., N.K.P., I.H.Z., M.R.P., E.A.N.; and manuscript editing, all authors

Disclosures of Conflicts of Interest: **K.L.N.** disclosed no relevant relationships. **T.Y.** disclosed no relevant relationships. **N.K.** disclosed no relevant relationships. **I.H.Z.** disclosed no relevant relationships. **C.G.V.** disclosed no relevant relationships. **S.I.S.** Activities related to the present article: institution received a grant from the British Heart Foundation/Medical Research Council. Activities not related to the present article: has a consultancy agreement and receives funding support from GlaxoSmithKline. Other relationships: disclosed no relevant relationships. **R.S.** disclosed no relevant relationships. **C.K.R.** disclosed no relevant relationships. **S.S.** Activities related to the present article: AMAG Pharmaceuticals supplied ferumoxytol free of charge. Activities not related to the present article: institution received an investigational research grant from Proteon Therapeutics. Other relationships: disclosed no relevant relationships. **K.K.W.** disclosed no relevant relationships. **L.M.G.** disclosed no relevant relationships. **D.S.** disclosed no relevant relationships. **M.D.H.** disclosed no relevant relationships. **M.R.P.** disclosed no relevant relationships. **M.A.F.** disclosed no relevant relationships. **M.L.S.** Activities related to the present article: disclosed no relevant relationships. Activities not related to the present article: is a shareholder in Healthmyne, Stemina Biomarker Discovery, and X-Vax. Other relationships: institution was issued a patent for CT scoring of mucus plugs. **G.H.R.** disclosed no relevant relationships. **A.R.** disclosed no relevant relationships. **D.E.N.** disclosed no relevant relationships. **E.A.N.** Activities related to the present article: institution received a grant from AMAG Pharmaceuticals to partially fund two of the OHSU clinical trials of MRI with ferumoxytol; ferumoxytol USPIO nanoparticles were donated by AMAG pharmaceuticals for some of the OHSU studies. Activities not related to the present article: disclosed no relevant relationships. Other relationships: disclosed no relevant relationships. **M.R.B.** Activities related to the present article: disclosed no relevant relationships. Activities not related to the present article: institution received grants from Siemens Healthcare, NGM Biopharmaceuticals, Madrigal Pharmaceuticals, Pinnacle Clinical Research, Metacrine, and ProSciento. Other relationships: disclosed no relevant relationships. **P.H.** disclosed no relevant relationships. **J.P.F.** disclosed no relevant relationships.

References

1. Wahsner J, Gale EM, Rodríguez-Rodríguez A, Caravan P. Chemistry of MRI contrast agents: current challenges and new frontiers. *Chem Rev* 2019;119(2):957–1057.
2. McDonald RJ, Levine D, Weinreb J, et al. Gadolinium retention: a research roadmap from the 2018 NIH/ACR/RSNA workshop on gadolinium chelates. *Radiology* 2018;289(2):517–534.
3. Daftari Besheli L, Aran S, Shaqdan K, Kay J, Abujudeh H. Current status of nephrogenic systemic fibrosis. *Clin Radiol* 2014;69(7):661–668.
4. U.S. Food and Drug Administration. Medical imaging drugs advisory committee meeting briefing document: gadolinium retention after gadolinium based contrast magnetic resonance imaging in patients with normal renal function <https://www.fda.gov/media/107133/download>. Published September 8, 2017. Accessed January 1, 2018.
5. Bashir MR, Bhatti L, Marin D, Nelson RC. Emerging applications for ferumoxytol as a contrast agent in MRI. *J Magn Reson Imaging* 2015;41(4):884–898.
6. Finn JP, Nguyen KL, Hu P. Ferumoxytol vs. Gadolinium agents for contrast-enhanced MRI: Thoughts on evolving indications, risks, and benefits. *J Magn Reson Imaging* 2017;46(3):919–923.
7. Balakrishnan VS, Rao M, Kausz AT, et al. Physicochemical properties of ferumoxytol, a new intravenous iron preparation. *Eur J Clin Invest* 2009;39(6):489–496.
8. Anzai Y, Prince MR, Chenevert TL, et al. MR angiography with an ultrasmall superparamagnetic iron oxide blood pool agent. *J Magn Reson Imaging* 1997;7(1):209–214.
9. Han F, Zhou Z, Han E, et al. Self-gated 4D multiphase, steady-state imaging with contrast enhancement (MUSIC) using rotating cartesian K-space (ROCK): Validation in children with congenital heart disease. *Magn Reson Med* 2017;78(2):472–483.
10. Nguyen KL, Moriarty JM, Plotnik AN, et al. Ferumoxytol-enhanced MR angiography for vascular access mapping before transcatheter aortic valve replacement in patients with renal impairment: a step toward patient-specific care. *Radiology* 2018;286(1):326–337.
11. Nguyen KL, Park EA, Yoshida T, Hu P, Finn JP. Ferumoxytol enhanced black-blood cardiovascular magnetic resonance imaging. *J Cardiovasc Magn Reson* 2017;19(1):106.
12. Walker JP, Nosova E, Sigovan M, et al. Ferumoxytol-enhanced magnetic resonance angiography is a feasible method for the clinical evaluation of lower extremity arterial disease. *Ann Vasc Surg* 2015;29(1):63–68.
13. Alam SR, Shah AS, Richards J, et al. Ultrasmall superparamagnetic particles of iron oxide in patients with acute myocardial infarction: early clinical experience. *Circ Cardiovasc Imaging* 2012;5(5):559–565.
14. U.S. Food and Drug Administration. FDA Drug Safety Communication: FDA strengthens warnings and changes prescribing instructions to decrease the risk of serious allergic reactions with anemia drug Feraheme (ferumoxytol). <http://www.fda.gov/Drugs/DrugSafety/ucm440138.htm>. Accessed March 30, 2015.
15. Ning P, Zucker EJ, Wong P, Vasanawala SS. Hemodynamic safety and efficacy of ferumoxytol as an intravenous contrast agents in pediatric patients and young adults. *Magn Reson Imaging* 2016;34(2):152–158.
16. Muehe AM, Feng D, von Eyben R, et al. Safety report of ferumoxytol for magnetic resonance imaging in children and young adults. *Invest Radiol* 2016;51(4):221–227.
17. Nguyen KL, Yoshida T, Han F, et al. MRI with ferumoxytol: A single center experience of safety across the age spectrum. *J Magn Reson Imaging* 2017;45(3):804–812.
18. Varallyay CG, Toth GB, Fu R, et al. What does the boxed warning tell us? safe practice of using ferumoxytol as an mri contrast agent. *AJNR Am J Neuroradiol* 2017;38(7):1297–1302.
19. Wise-Faberowski L, Velasquez N, Chan F, Vasanawala S, McElhinney DB, Ramamoorthy C. Safety of ferumoxytol in children undergoing cardiac MRI under general anaesthesia. *Cardiol Young* 2018;28(7):916–921.
20. Harris PA, Taylor R, Thielke R, Payne J, Gonzalez N, Conde JG. Research electronic data capture (REDCap)—a metadata-driven methodology and workflow process for providing translational research informatics support. *J Biomed Inform* 2009;42(2):377–381.
21. National Cancer Institute. Common Terminology Criteria for Adverse Events, v4.0 and v5.0. http://ctep.cancer.gov/protocolDevelopment/electronic_applications/ctc.htm#ctc_40. Accessed December 19, 2015.
22. American College of Radiology. Manual on Contrast Media (Version 10.3). https://www.acr.org/-/media/ACR/Files/Clinical-Resources/Contrast_Media.pdf. Accessed January 27, 2018.
23. Macdougall IC, Bircher AJ, Eckardt KU, et al. Iron management in chronic kidney disease: conclusions from a “Kidney Disease: Improving Global Outcomes” (KDIGO) Controversies Conference. *Kidney Int* 2016;89(1):28–39.
24. Fishbane S, Ungureanu VD, Maesaka JK, Kaupke CJ, Lim V, Wish J. The safety of intravenous iron dextran in hemodialysis patients. *Am J Kidney Dis* 1996;28(4):529–534.
25. Behzadi AH, Zhao Y, Ferooz Z, Prince MR. Immediate allergic reactions to gadolinium-based contrast agents: a systematic review and meta-analysis. *Radiology* 2018;286(2):731.
26. Bellin MF, Webb JA, Van Der Molen AJ, Thomsen HS, Morcos SK; Members of Contrast Media Safety Committee of European Society of Urogenital Radiology (ESUR). Safety of MR liver specific contrast media. *Eur Radiol* 2005;15(8):1607–1614.
27. Adkinson NF, Strauss WE, Macdougall IC, et al. Comparative safety of intravenous ferumoxytol versus ferric carboxymaltose in iron deficiency anemia: A randomized trial. *Am J Hematol* 2018;93(5):683–690.
28. Jahn MR, Andreasen HB, Fütterer S, et al. A comparative study of the physicochemical properties of iron isomaltoside 1000 (Monofer), a new intravenous iron preparation and its clinical implications. *Eur J Pharm Biopharm* 2011;78(3):480–491.
29. Bircher AJ, Auerbach M. Hypersensitivity from intravenous iron products. *Immunol Allergy Clin North Am* 2014;34(3):707–723, x–xi.
30. Santosh S, Podaralla P, Miller B. Anaphylaxis with elevated serum tryptase after administration of intravenous ferumoxytol. *NDT Plus* 2010;3(4):341–342.
31. Auerbach M, Kane RC. Caution in making inferences from FDA’s Adverse Event Reporting System. *Am J Health Syst Pharm* 2012;69(11):922–923.
32. Barton JC, Barton EH, Bertoli LF, Gothard CH, Sherrer JS. Intravenous iron dextran therapy in patients with iron deficiency and normal renal function who failed to respond to oral iron supplementation. *Am J Med* 2000;109(1):27–32.
33. Wang C, Graham DJ, Kane RC, et al. Comparative Risk of Anaphylactic Reactions Associated With Intravenous Iron Products. *JAMA* 2015;314(19):2062–2068.
34. Rhodes A, Evans LE, Alhazzani W, et al. Surviving Sepsis Campaign: International Guidelines for Management of Sepsis and Septic Shock: 2016. *Intensive Care Med* 2017;43(3):304–377.
35. Camaschella C. Iron-deficiency anemia. *N Engl J Med* 2015;372(19):1832–1843.